

terminal. Heart and kidney lying side by side at posterior end, heart on right, connected by a transverse renopericardial duct (Fig. 2d).

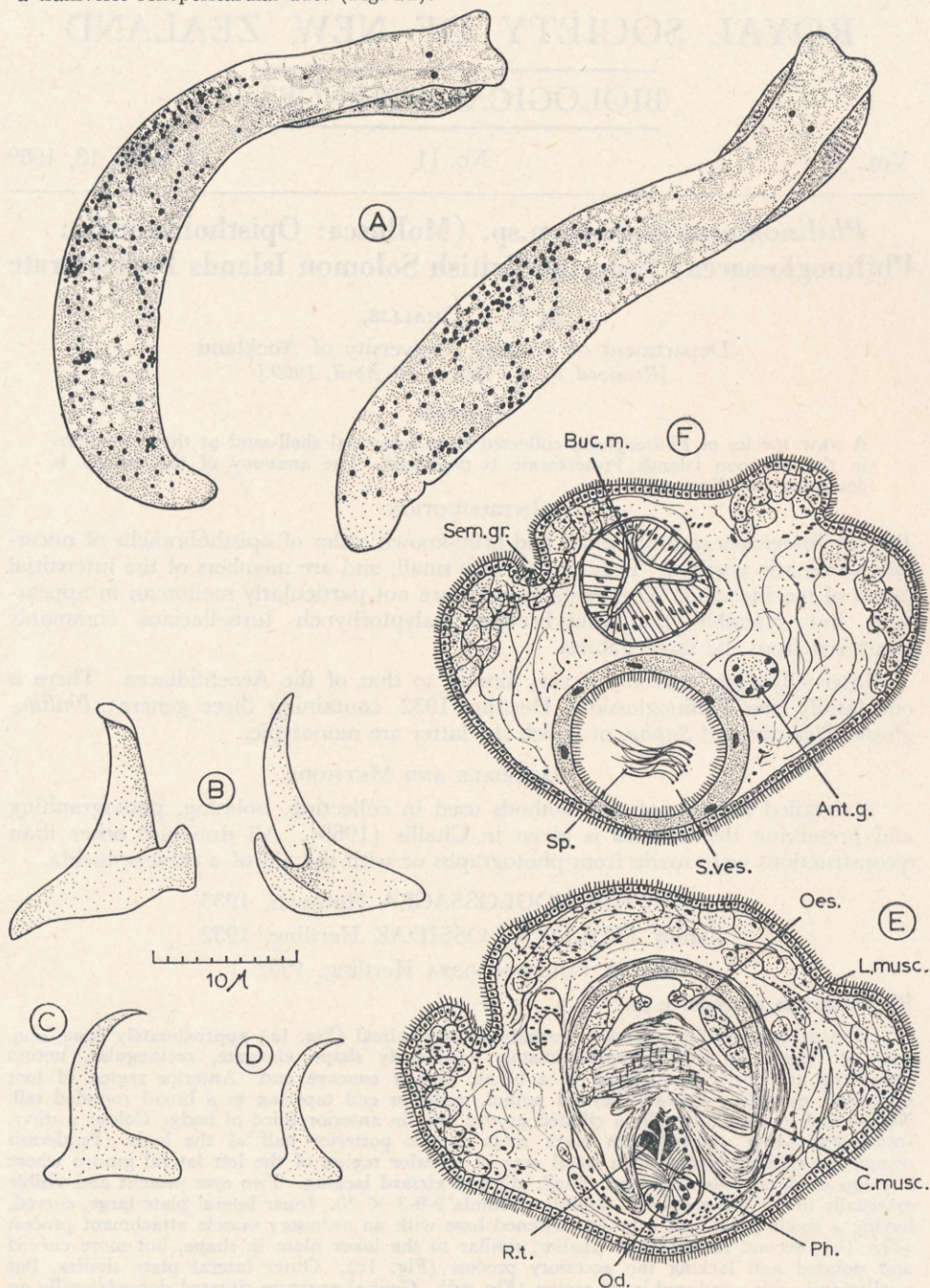


FIG. 1.—*Philinoglossa marcusii* n.sp. A. Two views of the living animal from photographs. B. Two aspects of an inner lateral plate of the radula. C. The second of the three lateral plates of the radula. D. The outer of the three lateral plates of the radula. E. A transverse section through the buccal mass showing the musculature of the buccal mass and the radula *in situ*. F. A transverse section through the oesophagus and through the ventral seminal vesicle. (For abbreviations see Fig. 2.)